

Adult Extragenadal Retroperitoneal Dermoid Cyst Masquerading As Hydatid Cyst

Naganathbabu Obla Lakshmanamoorthy¹, Srinivasan Ulagendrapurumal²

¹(Professor and Head, Department of Surgical Gastroenterology, Government Royapettah Hospital, Kilpauk Medical College, Chennai- 600014, India)

²(Assistant Professor, Department of Surgical Gastroenterology, Government Royapettah Hospital, Kilpauk Medical College, Chennai- 600014, India)

Abstract: Extragenadal germ cell tumors in the retroperitoneum are not common in adults. Dermoid cysts are congenital tumors consisting of derivatives from the ectoderm, endoderm and mesoderm germ cell layers. The imaging findings are distinctive. The present report is a case of a retroperitoneal dermoid cyst in a 22-year-old male patient which was excised in toto and histopathological examination confirmed the diagnosis of dermoid cyst.

Key words- abdominal mass, adult, dermoid, extragenadal, retroperitoneum

I. Introduction

Retroperitoneum is a rare location for the development of dermoid cyst in adults. They are usually encountered in infants and children. It occurs due to the aberrant migration of germ cells from the yolk sac during fetal development[1]. It commonly occurs in midline structures and gonadal structures. Testes and ovaries are the most common sites of involvement[2]. The involvement of extragenadal sites in decreasing order of frequency are mediastinum, sacrococcygeal region, retroperitoneum and pineal gland [3, 4, 5]. It is composed of somatic cell types from two or more germ layers (ectoderm, mesoderm or endoderm)[6].

We present a rare case of retroperitoneal dermoid cyst in a 22 year old male which was successfully treated with surgical resection.

II. Case Report

Twenty two year old male presented with a history of lower abdominal distension and left flank pain of 6 months duration. Pain was dull aching and mild in severity. There was no history of vomiting. No urinary symptoms. Bowel habits were normal. Appetite was good. There was no history of trauma. Clinically patient's general condition was good. Abdominal examination revealed a nontender smooth mass over the lumbar region, iliac fossa and hypogastrum. Digital rectal examination was normal. Contrast enhanced CT scan revealed multiple tiny floating cystic lesions within a large encapsulated mass of about 22cm x 16 cm mimicking a hydatid cyst (Fig. 1) The mass was compressing the left ureter with a moderate hydronephrosis on the left side. The hematological and biochemical parameters were normal. Serum AFP was normal.

Laparotomy was done after stenting the ureters. The cystic mass was found to be adherent to the left ureter and displacing the sigmoid colon. The ureter was carefully dissected out and the mass was excised in toto. Cut section of the mass revealed pultaceous material and hair (Fig. 2). Post operative period was uneventful. Patient is on regular follow up. Histopathology report revealed cyst lined by squamous epithelium with skin, sebaceous glands, sweat glands and fibrous connective tissue consistent with dermoid cyst (Benign cystic teratoma) (Fig. 3).

III. Discussion

Dermoid cyst is a cystic teratoma that contains an array of developmentally mature and solid tissues. Retroperitoneum is a rare site for dermoid cyst. Other rare sites being mediastinum, sacrococcygeal region and central nervous system. Primary retroperitoneal teratoma constitutes about 1-11% of all primary retroperitoneal tumors [7]. Around 43-45% of retroperitoneal teratomas are diagnosed within the first year of life and 10-20% after 30 years of age [8]. Adult retroperitoneal dermoid cyst commonly affects females. There is 25 % chance of malignancy, malignant degeneration being higher in adults than in children (25.8% vs 6.8%) [9]. Differential diagnosis of retroperitoneal cysts includes retroperitoneal sarcoma, hydatid cyst, ovarian tumor, mesenteric cyst and renal tumors.

Imaging modalities like CECT and MRI are useful for diagnosis and assessment of resectability. Ultrasonogram of testes is mandatory because 50% of men with retroperitoneal tumors also have testicular malignancy [10]. Serum tumor markers like CEA, AFP and CA19-9, should be measured in patients suspected for malignancy [9].

Complete excision is the treatment of choice. Marsupialization or draining of the cyst usually results in a recurrence. Spillage of cyst contents may lead to infection or recurrence. If histopathology reveals malignant change, adjuvant chemo and radiotherapy will be required.

IV. Conclusion

Primary extragenadal retroperitoneal dermoid cyst is rare in adults. Surgical resection remains the mainstay of treatment with an excellent five year survival. Though it is a rare condition, it should be included in the differential diagnosis of intraabdominal hydatid disease.

References

- [1]. Kanizsai B, Turi Z, Szigetvari I, Doszpod J. Sonographic diagnosis of a retroperitoneal dermoid cyst in a young girl. *Ultrasound Obstet Gynecol* 1998;12:367-8
- [2]. Lane RH, Stephens DH, Reiman HM. Primary retroperitoneal neoplasms: CT finding in 90cases with clinical and pathologic correlation. *AJR Am J Roentgenol* 1989;152:83-9
- [3]. McKenney JK, Heerema-McKenney A, Rouse RV. Extragenadal germ cell tumors: a review with emphasis on pathologic features,clinical prognostic variables,and differential diagnostic considerations.*Adv Anat Pathol* 2007;14:69-92
- [4]. Ueno T, Tanaka YO, Nagatha M, Tsunoda H, Anno I, Ishikawa S, Kawai K, Itai Y. Spectrum of germ cell tumors: from head to toe. *Radiographics* 2004;24:387-404
- [5]. Schmoll HJ. Extragenadal germ cell tumors. *Ann Oncol*2002;13:S265-S272.
- [6]. R.J.Motzer and B.J.George, "Testicular cancer" in *Harrisons Principles of Internal Medicine*,17E,A.S.Fauci,E.Braunwald,D.L.Kasper,et al., chapter 92 <http://www.accessmedicine.com/content.aspx?a ID= 2866870>
- [7]. Horton Z, Schlatter M, Schultz S. Pediatric germ cell tumors. *Surg Oncol* 2007;16:205-213
- [8]. Panageas E. General diagnosis case of the day. Primary retroperitoneal teratoma. *AJR Am J Roentology* 1991;156:1292-1294
- [9]. Lambriandes A L, Walker M M, Rosin R D. Primaryretroperitoneal teratoma in adults. *Urology*1987;29:310-2
- [10]. T.Gilligan and P.Kantoff, "Extragenadal germ cell tumors involving the mediastinum and retroperitoneum", in *UpToDate Patient Preview*,W.K.Oh,Ed.,UpToDate,(Waltham,Mass,USA) 2009

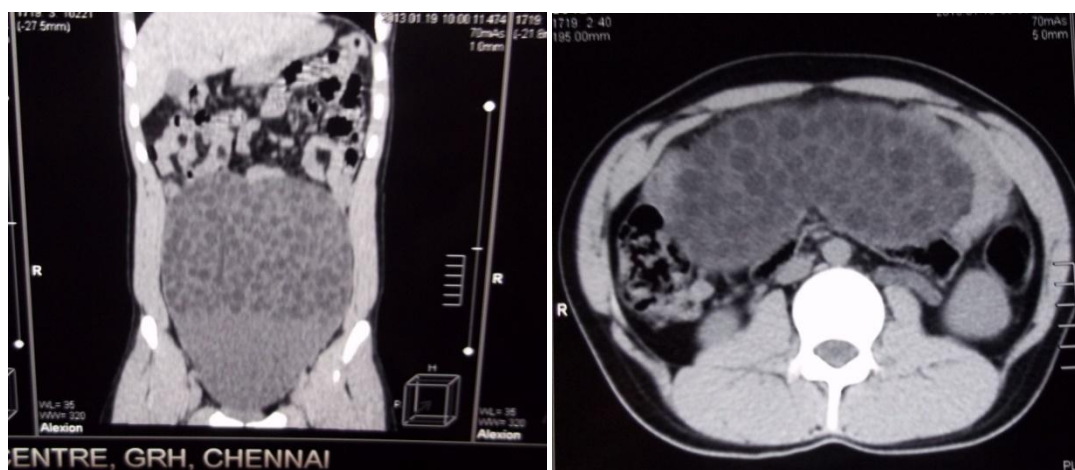


Fig.1. CECT abdomen showing multiple tiny, floating cystic lesions within a large encapsulated mass mimicking hydatid cyst.

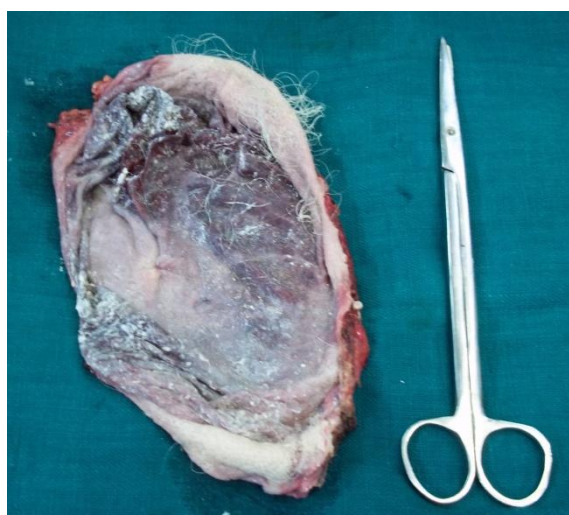

Fig.2. Cut open specimen showing pultaceous material and hair.

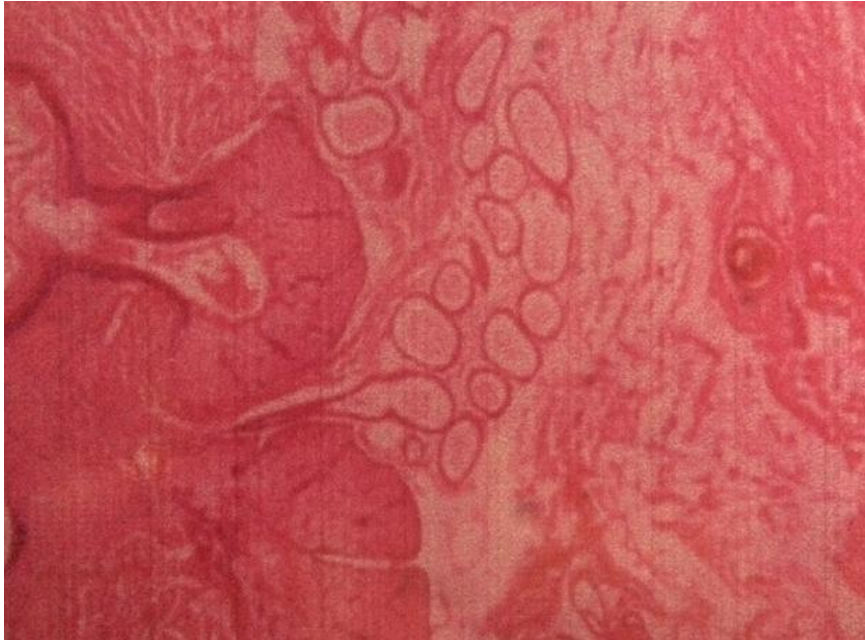

Fig.3. Histopathology showing a cystic lesion lined by squamous epithelium with skin, sebaceous glands, sweat glands and fibrous connective tissue consistent with dermoid cyst.